Journal of Health and Medical Sciences

Chandra, Kris, and Kurniawan, M. Budi. (2021), Ultrasound Guided Brachiocephalic Vein Cannulation using Supraclavicular Approach. In: *Journal of Health and Medical Sciences*, Vol.4, No.4, 6-10.

ISSN 2622-7258

DOI: 10.31014/aior.1994.04.04.187

The online version of this article can be found at:
https://www.asianinstituteofresearch.org/

Published by:
The Asian Institute of Research

The Asian Institute of Research *Journal of Health and Medical Sciences* is a peer-reviewed International Journal. The journal covers scholarly articles in the fields of Medicine and Public Health, including medicine, surgery, ophthalmology, gynecology and obstetrics, psychiatry, anesthesia, pediatrics, orthopedics, microbiology, pathology and laboratory medicine, medical education, research methodology, forensic medicine, medical ethics, community medicine, public health, community health, behavioral health, health policy, health service, health education, health economics, medical ethics, health protection, environmental health, and equity in health. As the journal is Open Access, it ensures high visibility and the increase of citations for all research articles published. The *Journal of Health and Medical Sciences* aims to facilitate scholarly work on recent theoretical and practical aspects of Health and Medical Sciences.

Asian Institute of Research
Connecting Scholars Worldwide

The Asian Institute of Research
Journal of Health and Medical Sciences
Vol.4, No.4, 2021: 6-10
ISSN 2622-7258

DOI: 10.31014/aior.1994.04.04.187

Ultrasound Guided Brachiocephalic Vein Cannulation using Supraclavicular Approach

Kris Chandra[1], M. Budi Kurniawan[2]

[1,2] Department of Anesthesiology and Intensive Care, Padjajaran University, Bandung, Indonesia

Correspondence: Kris Chandra, Department of Anesthesiology and Intensive Care, Padjajaran University, Bandung, Indonesia. Tel: +6281387318883. E-mail: kris.chandra@ymail.com

Abstract
The need of central vein cannulation has been increased since the increased case of critical patients and patients underwent high-risk patients. Supraclavicular approach of central vein cannulation is an alternative approach to central vein cannulation due to fewer anatomical variance, good longitudinal vein view, better visualization of needle during procedure, clear demarcation of landmarks, larger target area, better patient comfort, and fewer complications. This case study presents an ultrasound guided central vein cannulation using supraclavicular approach in 30 year old male patient diagnosed with septic shock, anemia, trombcytopenia, and electrolyte imbalance post laparotomy. The indication of central vein cannulation in the patient was to deliver volume resuscitation, to provide emergency vein access, to provide nutritional support, to deliver chemically caustic agents, and central vein pressure monitoring.

Keywords: Central Vein Cannulation, Complication, Critical Care, Supraclavicular Approach, Brachiocephalic Vein

1. Introduction

Fast and secure access to central vein circulation is one of the most essential interventions in critical care. The need of central vein cannulation has been increasing steadily as patients in critical state or patients whom underwent high risk operastion rise. Central vein cannulation has several goals: (1) to perform fluid resuscitation, (2) to monitor central vein pressure, (3) to collect routine blood sampling, (4) to provide access for transvenous pacing, (5) to provide hemodyalisis access route, (6) to deliver continuous administration of inotropes and hypertonic fluids.

Central vein cannulation is routinely performed in internal juguar vein, subclavian vein, femoralis vein, or peripherally from basilic vein. Choosing the site of insertion had direct correlation with cannulation success rate. Various catheter placement has been developed with both risk and benefit, and varying success rates. (Turcotte et al., 2006; *Colomb Med*, n.d.)

Percutaneous cannulation to subclavian vein using subclavian approach has been described throroughly, as the approach is associated with several complications such as unintended arterial puncture, pneumothorax, and hemothorax which contributes to morbidity and mortality. Supraclavicular approach was first reported in 1965 with more notifiable benefit compared to infraclavicular approach. Supraclavicular approach was less often performed due to concern of unintended injury and complication such as unintended puncture to thoracic cavity, direct puncture damage to important structure, and several barriers making it harder to identify anatomical landmarks, predict angle of insertion, and expected needle track contributing to failure rate. (Hind et al., 2003; Tomar et al., 2013)

In this case study, we presented a case of central vein cannulation through brachiocephalic vein using supraclavicular approach and literature review which covered indication, contraindication, and its comparison to other approaches.

2. Case Report

A 30-year-old male was admitted to emergency department diagnosed with septic shock, anemia, thrombocytopenia, hypoalbuminemia. He had history of ileal resection, double barrel ileostoma, and adhesiolysis due to complete ileal obstruction. He was in critical state and was given midazolam 3mg/hour for sedation. Blood pressure was 118/65 mmHg supported by norepinephrine 0,1mcg/kg/min, heart rate of 108 times/minute and respiratory rate of 20-24 times/min. He was on ventilator. Peripheral oxygen saturation was 99%. He was anemic and thrombocytopenic, with normal coagulation factors (table 1). His chest x-ray was clear with cardiomegaly without signs of congestion (figure 1).

Table 1: Routine blood panel result

Parameter	Result
Hemoglobin	10,3 gr/dL
Thrombocyte	51.000 cell/dL
PT / APTT	14”/ 38,3”
INR	1,28
Albumin	1,63 gr/dL
Kalium	5,1 mEq/L
Lactate	5,0mg/dL

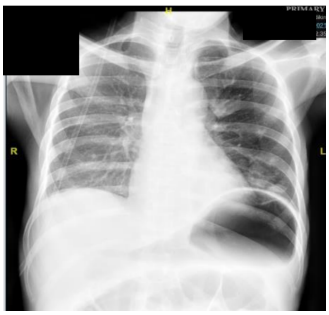

Figure 1: Chest X-ray

Cannulation of brachiocephalic venin using supraclavicular approach was performed due to collapsed internal jugular vein. Indication of central vein cannulation in the patient was: (1) to provide emergency vein access, volume resuscitates, and blood transfusion (2) to provide access for albumin correction using 100 ml of 20% albumin fluid, (3) to provide access for nutritional support, and (4) to monitor central vein pressure.

3. Discussion

Central vein cannulation in patient with a critical state is a life-saving procedure to provide access for volume resuscitate, drug deliver, rapid electrolyte correction, and monitoring central vein pressure. Central vein cannulation can be performed throug internal jugularis vein (IJV), femoral vein (FV), dan subclavian vein (SV).

Percutaneous puncture to the IJV can be performed anteriorly, centrally, or posteriorly. Central approach is the most common. Cannulation was performed with a percutaneous puncture in the superior triangular area, 45o from the coronal plane, aimed to the sagital plane. (Hind et al., 2003; *Colomb Med*, n.d.)

FV cannulation is an alternative in intubated and when chest compression is performed to provide fast venous access. Cannulation was performed in the superior anterior aspect of the thigh, directly under the inguinal ligament. Anatomically, femoral artery divides the inguinal ligament into two segments, medially and laterally. Vein puncture was performed 1 cm medially from the maximal palpable impulse of the femoral artery (*Colomb Med*, n.d.).

SV cannulation was performed commonly using subclavicular and supraclavicular approaches. Supraclavicular approach uses junction of lateral clavicle to the strenocleidomastoid muscle clavicular head. The puncture was performed 1 cm superolaterally from the junction. The needle was inserted at 5-15o angle and proceeded to an imaginary line that divided the claviculosternomastoid angle into two. Central vein puncture was perfomed between the clavicle and the anterior scalene muscle (*Colomb Med*, n.d.). Supraclavicular approach in brachiocephalic cannulation was performed in sterial manner using seldinger technique. The patient was put into trendelenburg (-30o) using blanket rolls and the head was tilted to the opposite side of the cannulation. (figure 2). Portable ultrasound was used with 12Hz linear and 8 Hz microconvex probe. 2D doppler study showed color/flow in IJV, SV, and brachiocephalic vein to assess anatomical features, size of the vein, and its permeability.

To visualize brachiocephalic vein, IJV and carotid artery were first found and identified, and the probe was advanced caudally alongside with IJV into the supraclavicular fossa. The probe may be tilted anteriorly to better provide visualization of SV and brachiocephalic vein at its long axis (figure 3).

To assess safety of the needle path, subclavian artery, subclavian vein, and brachiocephalic vein must be identified using tilt manouver. Pleural line was also identified and aortic arch was important to be considered when insertion of brachiocephalic vein was performed from the left side. Skin was punctured using introducer and a wire was placed carefully after confirmed central vein cannulation has been established. Placement of cannulation alongside the wire path can be performed as routine care (MacDonnell et al., 1992).

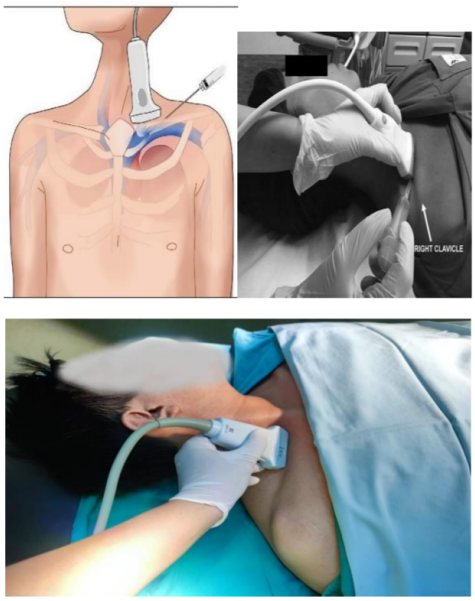

Figure 2: Ultrasound probe positioning and needle path in the supraclavicular approach.

(MacDonnell et al., 1992)

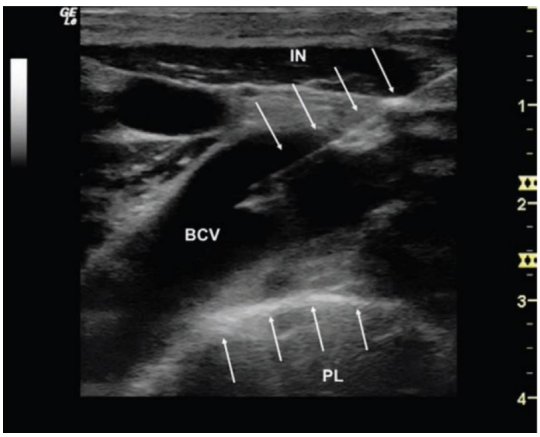

Figure 3: *longitudinal view* BCV *in-plane approach*. (IN, inserted needle, IN; pleural line, PL)

Several reason has made supraclavicular approach is more common than infaclavicular approach were a more commonly identified structure (clavi-sternocleidomastoid angle), more superficial vein location, larger target area, and more direct access to the subclavian vein. The site was lesser corelated to lung complications (table 2) with better success rate (table 3).

Table 2: Success rate and complication of central vein cannulation. (3)

	Supra-klavikula	IJV	Sub-klavikula	Femoral
Arterial puncture	0,8-3,36	6,3-9,1	3,1-4,9	9,0-15,0
Hema-toma	Not applicable	<0,1-2,2	1,2-2,1	9,0-15,0
Hemo-thorax	Not applicable	Tidak tersedia	0,1-0,6	Not applicable
Pneumo-thorax	0,48-0,56	<0,1-0,2	1,5-3,1	Not applicable
Thrombo-sis	Not applicable	7,6	1,9	21,5

Table 3: Morbidity rate and transfusion rate along with it's associated approach. (Tomar et al., 2013)

	Supraklavikula (Czarnik dkk.)[6]	Supra-clavicular	Infra-clavicula	Jugular interna
Complication rate	1,7% (0,6-3,6)	0,56-2%	1-10%	1-5%
Success rate	92% (88,7-94,6)	74-98%	80-95%	90-99%

4. Conclusion

Ultrasound guidance has been reported to increase safety during IJV, FV, and SV cannulation. While ultrasound contributes directly to CVC placement, ultrasound machine is not always present. Anatomic landmark approach

is essential while inserting the central vein catheter. Supraclavicular approach is considered safe for use. Until now, there was no better approach zoom capacity in the operator room MRI.

References

Umaña, M., García, A., Bustamante, L., Castillo, J. L., & Sebastián Martínez, J. (n.d.). Variations in the anatomical relationship between the common carotid artery and the internal jugular vein. *Colombia Médica : CM*, *46*(2), 54–59.

Turcotte, S., Dubé, S., & Beauchamp, G. (2006). Peripherally inserted central venous catheters are not superior to central venous catheters in the acute care of surgical patients on the ward. World Journal of Surgery, 30(8), 1605–1619. https://doi.org/10.1007/s00268-005-0174-y

Tomar, G. S., Chawla, S., Ganguly, S., Cherian, G., & Tiwari, A. (2013). Supraclavicular approach of central venous catheter insertion in critical patients in emergency settings: Re-visited. Indian Journal of Critical Care Medicine : Peer-Reviewed, Official Publication of Indian Society of Critical Care Medicine, 17(1), 10–15. https://doi.org/10.4103/0972-5229.112145

Hind, D., Calvert, N., McWilliams, R., Davidson, A., Paisley, S., Beverley, C., & Thomas, S. (2003). Ultrasonic locating devices for central venous cannulation: Meta-analysis. BMJ : British Medical Journal, 327(7411), 361.

MacDonnell, J. E., Perez, H., Pitts, S. R., & Zaki, S. A. (1992). Supraclavicular subclavian vein catheterization: Modified landmarks for needle insertion. Annals of Emergency Medicine, 21(4), 421–424. https://doi.org/10.1016/S0196-0644(05)82663-0

Czarnik, T., Gawda, R., Perkowski, T., & Weron, R. (2009). Supraclavicular Approach Is an Easy and Safe Method of Subclavian Vein Catheterization Even in Mechanically Ventilated Patients. *Anesthesiology*, *111*(2), 334–339. https://doi.org/10.1097/ALN.0b013e3181ac461f